

Short Communication

Stellate ganglion block reduces symptoms of Long COVID: A case series

Luke D. Liu, Deborah L. Duricka*

Neuroversion Inc., Anchorage, AK, USA



ARTICLE INFO

Keywords:

Long COVID/PASC
 Myalgic encephalitis/chronic fatigue syndrome (ME/CFS)
 Postural orthostatic tachycardia syndrome (POTS)
 Dysautonomia
 Stellate ganglion block
 Cerebral blood flow

ABSTRACT

After recovering from COVID-19, a significant proportion of symptomatic and asymptomatic individuals develop Long COVID. Fatigue, orthostatic intolerance, brain fog, anosmia, and ageusia/dysgeusia in Long COVID resemble “sickness behavior,” the autonomic nervous system response to pro-inflammatory cytokines (Dantzer et al., 2008). Aberrant network adaptation to sympathetic/parasympathetic imbalance is expected to produce long-standing dysautonomia. Cervical sympathetic chain activity can be blocked with local anesthetic, allowing the regional autonomic nervous system to “reboot.” In this case series, we successfully treated two Long COVID patients using stellate ganglion block, implicating dysautonomia in the pathophysiology of Long COVID and suggesting a novel treatment.

1. Introduction

The global pandemic caused by the SARS-CoV-2 virus has resulted in millions of deaths and untold suffering worldwide. Most individuals mount a sufficient immune response with an acute phase that clears the virus and then resolves normally. In asymptomatic cases, unusually robust inflammation is well-controlled and C reactive protein (CRP) remains within normal range (Li et al., 2021) while an effective immune response is mounted (Le Bert et al., 2021). In symptomatic cases, inflammatory cytokines and CRP rise dramatically and correlate with disease severity, but return to normal within a few months following resolution of infection regardless of COVID-19 severity (Sonnweber et al., 2020). Time to resolution of symptoms may be prolonged in cases with organ damage, but generally correlates with severity of disease course. However, approximately 30% of symptomatic and 5% of asymptomatic individuals who recover from acute infection develop a distinct proinflammatory cytokine/chemokine profile (Patterson et al., 2021) and experience a range of symptoms that persist indefinitely (Logue et al., 2021). The constellation of symptoms, which can range from mild to debilitating, is known colloquially as “Long COVID” and formally as Post-Acute Sequelae of SARS-CoV-2 infection (PASC). Symptoms can include fatigue, orthostatic intolerance, elevated resting heart rate, shortness of breath, brain fog, sleep disturbance, fevers, gastrointestinal symptoms, anosmia, dysgeusia, anxiety, and depression according to the World Health Organization clinical case definition (Soriano et al., 2021). Dysautonomia, specifically excessive sympathetic

nervous system activity, has been implicated in comorbidities of severe COVID-19 (Porzionato et al., 2020), short-term recovery from acute COVID-19 (Stute et al., 2021), and Long COVID (Barizien et al., 2021; Dani et al., 2021).

Sympathetic innervation to the head, neck, upper limbs, and upper thoracic region including the thymus, heart, lungs and the lacrimal, salivary, thyroid, and pineal glands is provided by the cervical sympathetic chain, which consists of the superior cervical ganglion, middle cervical ganglion, inferior cervical ganglion, and first thoracic ganglion. In 80% of the population the inferior cervical and first thoracic ganglia are fused to form the stellate ganglion. Injection of local anesthetic near the stellate ganglion can block activity of the entire cervical sympathetic chain, as evidenced by the physiological signs of a successful block stellate ganglion block (SGB) collectively known as “Horner’s Syndrome” which includes ipsilateral ptosis, miosis, anhidrosis, and facial flushing. SGB was described as early as the 1930s as a treatment for reflex sympathetic dystrophy of the upper limbs (White, 1930). The ability of the SGB to improve blood flow and deactivate sympathetic tone has also been useful in the treatment of Raynaud’s phenomenon and hyperhidrosis in the upper limbs (Rickles, 1977). Currently SGB is showing promise for treatment of post-traumatic stress disorder (Lipov et al., 2012; Mulvaney et al., 2014), cardiac arrhythmia (Tian et al., 2019), and hot flashes associated with cancer treatment and menopause (Othman and Zaky, 2014; Rahimzadeh et al., 2018). Mechanisms for the durable central nervous system effects of the SGB in these conditions are unclear, delaying its broad acceptance as a valid treatment.

* Corresponding author.

E-mail addresses: lliu@neuroversion.net (L.D. Liu), dduricka@neuroversion.net (D.L. Duricka).<https://doi.org/10.1016/j.jneuroim.2021.577784>

Received 3 November 2021; Received in revised form 26 November 2021; Accepted 4 December 2021

Available online 8 December 2021

0165-5728/© 2021 The Authors.

Published by Elsevier B.V. This is an open access article under the CC BY-NC-ND license

<http://creativecommons.org/licenses/by-nc-nd/4.0/>.

In this case series, we report sustained positive clinical outcomes for two Long COVID patients after treatment with SGB, identifying the pathophysiology for their symptoms as a regional sympathetically mediated dysautonomia and suggesting that SGB could be an effective intervention for at least a subset of Long COVID patients.

2. Case presentation

A 42-year-old female who recovered from a non-critical course of COVID with low oxygen saturation, fatigue, anosmia and dysgeusia, presented to our clinic eight months after onset of illness. After recovering from acute illness, she continued to experience debilitating fatigue, mental fogging, difficulty concentrating, elevated resting heart rate, sleep disturbance, lack of appetite and food aversion due to diminished and altered sense of taste and smell. She had been let go from her job and was teaching four-hour CPR courses with difficulty, relying on her teaching manual to recall facts and procedures previously well known to her. The unpalatability of food had led to a 30-pound weight loss that was continuing to progress.

The patient completed a numerical survey rating the severity of 13 common Long COVID symptoms at present (post-COVID), retrospectively for pre-COVID baseline, and at relevant timepoints after treatment (Fig. 1). We obtained appropriate consent and performed right-sided SGB. The patient noted immediate improvement in ipsilateral anosmia and dysgeusia as well as marked improvement in mental clarity and concentration. Anosmia and dysgeusia persisted contralaterally. Two days later we performed left-sided SGB. Immediately following the procedure, she experienced improvement in ipsilateral anosmia and dysgeusia, restoring olfactory and gustatory function bilaterally. After a follow-up appointment the next day, she was able to drive home without conscious effort to recall the route, demonstrating noticeable improvement in memory. Two weeks after her second SGB, the patient reported durable restoration of taste and smell, as well as refreshing sleep resembling her pre-COVID baseline. Notably, she was able to teach a

nine-hour course for CPR instructors without relying on written material, demonstrating a drastic improvement in recall. These improvements in symptoms were durable at 60-day follow-up (Fig. 1).

A 44-year-old female contracted COVID-19 approximately eight months prior to presentation to our clinic for treatment of Long COVID. Her initial COVID-19 symptoms were loss of smell and taste, mental fogging, headache, and dyspnea. Approximately one week after onset of acute symptoms her headache worsened, prompting evaluation in the ER but not hospitalization. Her headache symptoms dissipated over the following two weeks, but she experienced declining cognitive function and developed stuttering speech, significant cognitive impairment, and right-sided paresis, prompting hospitalization and evaluation for MCV. Her MRI demonstrated inflammation (symmetric increased FLAIR signal within the temporal horns bilaterally extending along the ependymal surfaces but not within the adjacent hippocampal complexes), but neither stroke nor viral encephalitis. She was discharged with ‘sequelae of COVID-induced ventriculitis’ as a leading consideration and prescribed intense occupational, physical, and speech therapy for profound memory deficits, speech impediment, impaired coordination, inability to concentrate, and debilitating fatigue. Despite these therapies, she was unable to continue her work as a special education teacher.

When the patient presented to our clinic after seven months of therapy, she continued to experience debilitating fatigue and speech impediment, and had returned only to limited duties and shortened hours at work. She reported that ongoing dysgeusia had led to food aversion and significant unintentional weight loss. She was experiencing severe generalized body pain described as dull with pins and needles that occasionally kept her bedbound. She noted that acute stress and mental or physical exertion exacerbated her right-sided motor deficits, fatigue, and cognitive issues. She also experienced intermittent headaches described as “crawling pain in my brain.”

After the patient completed assessment forms (Fig. 2) and provided consent, we performed right-sided SGB followed by left-sided SGB the following day. Within minutes of each procedure, the patient reported

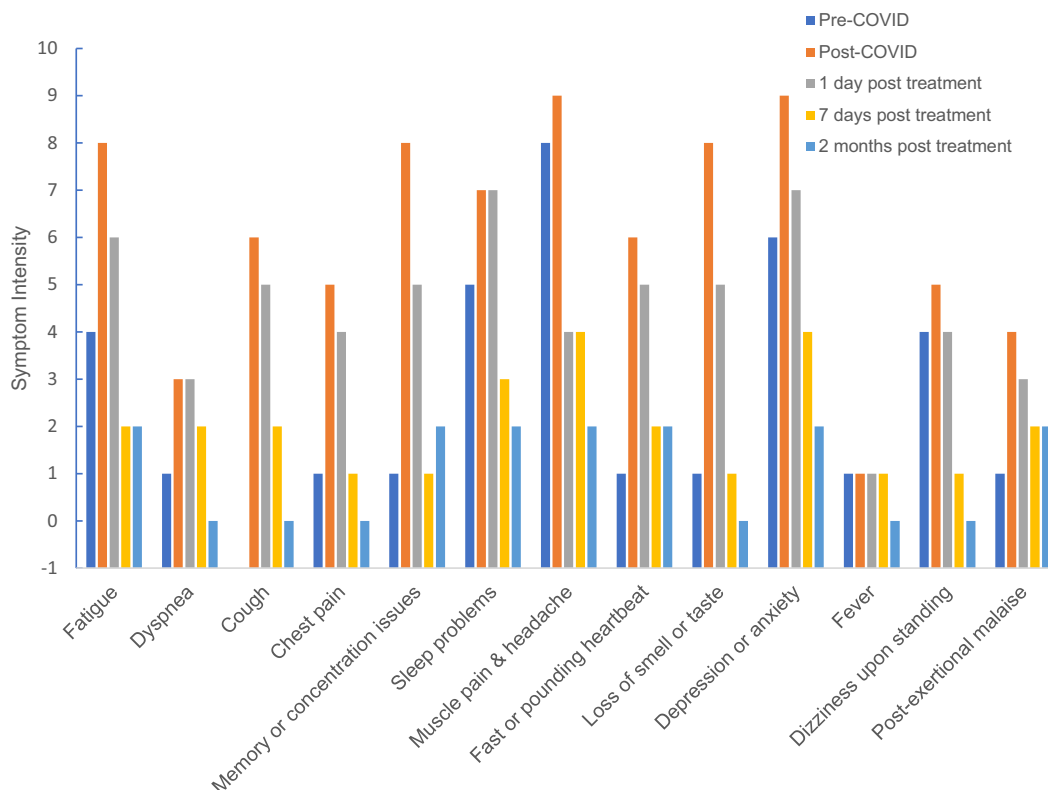


Fig. 1. Intensity of Long COVID symptoms over time. Data was collected retrospectively for Pre-COVID timepoint. NOTE: Y axis set to -1 to visualize a score of zero.

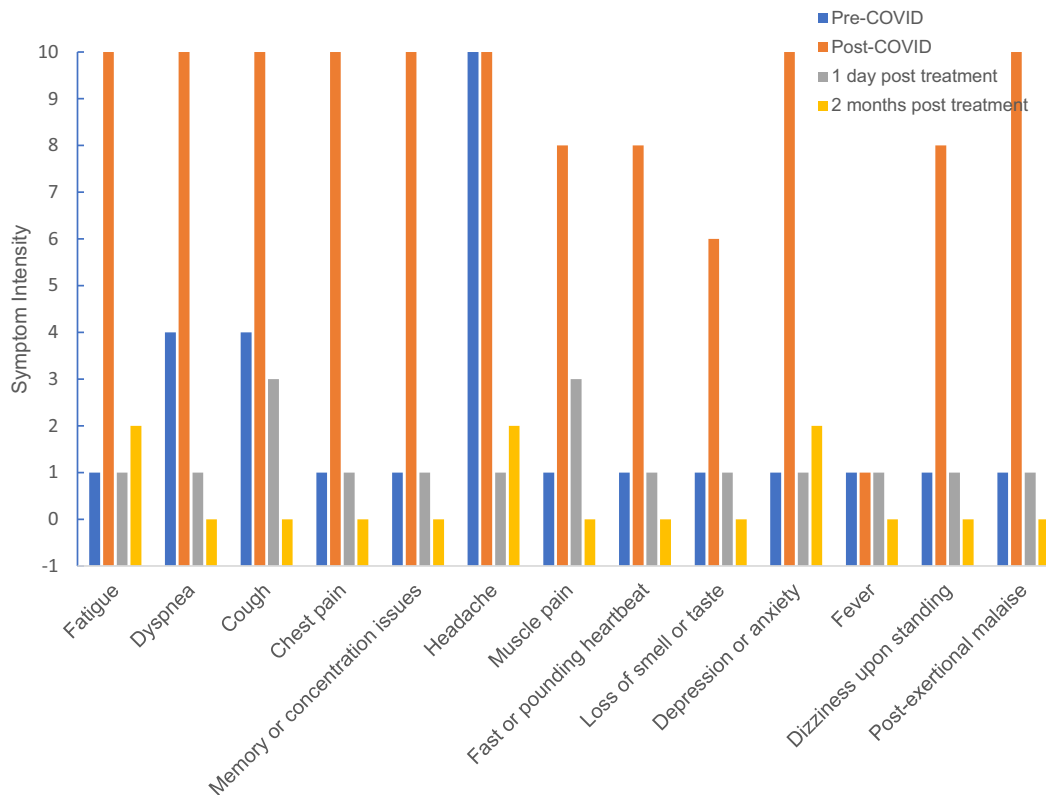


Fig. 2. Intensity of Long COVID symptoms over time. Data was collected retrospectively for Pre-COVID timepoint. NOTE: Y axis set to -1 to visualize a score of zero.

drastic improvement in ipsilateral anosmia and dysgeusia. At three-day follow-up she indicated that her physical and mental stamina had improved significantly, allowing her to perform routine household activities without debilitating lapses in memory. One week after treatment, she began a new job as a high-school teacher and was able to teach a full day of classes, which she states would have been impossible prior to treatment. On follow-up at two weeks, the patient reported durable resolution of stuttering and 75% improvement in all other symptoms. At 60-day follow-up she reported normal levels of fatigue and cognitive function, durable restoration of smell and taste, and absence of post-exertional malaise (Fig. 2).

3. Discussion

This case series describes the improvement of Long COVID symptoms after local anesthetic blockade of the cervical sympathetic chain bilaterally in two patients, suggesting that a regional sympathetically mediated process is involved in the maintenance of their Long COVID symptoms. This supports the theory that dysautonomia underlies the pathophysiology of at least a subset of Long COVID/PASC patients. The autonomic nervous system provides complex bidirectional communication between the immune system and the nervous system. Feedforward loops allow rapid response to infection, while feedback loops prevent damaging levels of inflammation (Tracey, 2009). Conditions that “preload” the sympathetic nervous system toward inflammation, (e.g., hypertension, obesity, diabetes) predispose catastrophic failure of this feedback loop, resulting in damaging cytokine levels seen in severe COVID-19 (Porzionato et al., 2020). The dysregulated neuro-inflammatory state observed in Long COVID (Patterson et al., 2021) represents a subtler form of dysautonomia that appears to be responsive to SGB.

The vagus nerve reports levels of catecholamines and cytokines to the brainstem, where multiple signals are integrated into behavioral responses (Dantzer et al., 2008), including sickness behaviors that

overlap significantly with Long COVID symptoms. Alterations in autonomic processes regulating homeostasis are appropriate during acute infection, but persistent sympathetic hyperactivity may result in neuronal adaptation that manifests as persistent dysautonomia similar to that seen in complex regional pain syndrome (CRPS)—in which an acute tissue injury produces long-standing vasomotor dysfunction, neurogenic inflammation, and aberrant neuroplasticity in the affected body region. While CRPS is usually associated with a limb, Long COVID seems to predominantly affect the brain. We believe that SGB-induced sympathectomy produces its beneficial effects in Long COVID by attenuating chronic sympathetic hyperresponsiveness, improving cerebral and regional blood flow, and recalibrating the autonomic nervous system toward pre-COVID homeostasis.

Whether or not SARS-CoV-2 is neuroinvasive is an open question (McQuaid et al., 2021). Although it can infect human brain organoids (Song et al., 2021), neuroinvasion appears uncommon except in severe COVID-19. Moreover, detection of virus in brain tissue following death from severe COVID-19 did not correlate with the degree of neuropathology (Matschke et al., 2020). The rapid resolution of symptoms after SGB makes cytopathic effect unlikely. It is possible that damage and structural recovery has taken place but the system needs to “reboot” to produce functional recovery.

Cerebral blood flow (CBF) in humans is affected by a variety of inputs and regulated by sympathetic fibers extending from the cervical sympathetic chain. Impaired CBF is associated with dysautonomia syndromes that share symptoms with Long COVID, namely myalgic encephalitis/chronic fatigue syndrome (ME/CFS) and postural orthostatic tachycardia syndrome (POTS). Compared to healthy controls, ME/CFS patients ubiquitously display reduced CBF and impaired cognitive function during orthostatic testing (van Campen et al., 2020a; van Campen et al., 2020b; Medow et al., 2014); impairment of CBF restoration is linearly related to disease severity (van Campen et al., 2021). After strenuous mental tasks, CBF fails to recover normally in regions involved in memory, goal-oriented attention, and visual function (Staud

et al., 2018). Similarly, impaired CBF and cognitive dysfunction are observed in POTS patients with orthostatic challenge and with a prolonged cognitive stress test (Wells et al., 2020).

Both SGB (Kang et al., 2010) and cervical ganglionectomy (ter Laan et al., 2013) increase CBF under normotensive conditions. Providing luxury perfusion (blood flow in excess of local metabolic requirements) should alleviate symptoms associated with impaired CBF. Improvement in anosmia after SGB has been reported previously, although the mechanism is unknown (Moon et al., 2007; Park et al., 2013; Moon et al., 2013). The immediate improvements in taste and smell reported by our patients may be due to increased CBF to brain structures responsible for these senses, or increased perfusion of the facial areas where the peripheral receptors for these senses reside. However, therapeutic duration of SGB is clinically observed to extend beyond that of local anesthesia, indicating mechanisms other than initial augmentation of regional blood flow by transient sympathetomy. Possibilities may include local recalibration of regional sympathetic influence, central integration of the effects of increased CBF, or rebalancing of the interaction between the nervous and immune systems. Investigation of the mechanism for the durable improvement of symptoms in our patients is beyond the scope of this clinical observation report, but is urgently warranted.

4. Conclusion

The stellate ganglion block has been used for nearly a century to treat a variety of sympathetically mediated medical conditions. Its safety profile is well established. Its application in treating Long COVID/PASC is novel but promising. The lack of effective treatments for Long COVID/PASC makes the SGB an attractive therapeutic modality that deserves further investigation.

Consent for publication

All patients provided consent to publish deidentified information for this case series report.

Funding

This research did not receive any specific grant from funding agencies in the public, commercial, or not-for-profit sectors.

Competing interests

Luke D Liu MD is the owner and CMO of Neuroversion Inc., an interventional pain clinic that provides services including stellate ganglion block. Deborah L Duricka PhD is Patient Care and Research Coordinator at the same. The authors declare no other competing interests.

Acknowledgements

The authors gratefully acknowledge Eugene Lipov MD for illuminating conversations about SGB and the autonomic nervous system, as well as spearheading the exploration of utilizing cervical sympathetic blocks for conditions related to dysautonomia.

References

- Barizien, N., Le Guen, M., Russel, S., et al., 2021. Clinical characterization of dysautonomia in long COVID-19 patients. *Sci. Rep.* 11, 14042. <https://doi.org/10.1038/s41598-021-93546-5>. PMID: 34234251; PMCID: PMC8263555.
- Dani, M., Dirksen, A., Taraborrelli, P., Torocastro, M., Panagopoulos, D., Sutton, R., Lim, P.B., 2021 Jan. Autonomic dysfunction in 'long COVID': rationale, physiology and management strategies. *Clin. Med. (Lond)* 21 (1), e63–e67. <https://doi.org/10.7861/clinmed.2020-0896>. Epub 2020 Nov 26. PMID: 33243837; PMCID: PMC7850225.

- Dantzer, R., O'Connor, J.C., Freund, G.G., Johnson, R.W., Kelley, K.W., 2008 Jan. From inflammation to sickness and depression: when the immune system subjugates the brain. *Nat. Rev. Neurosci.* 9 (1), 46–56. <https://doi.org/10.1038/nrn2297>. PMID: 18073775; PMCID: PMC2919277.
- Kang, C.K., Oh, S.T., Chung, R.K., Lee, H., Park, C.A., Kim, Y.B., Yoo, J.H., Kim, D.Y., Cho, Z.H., 2010 Oct. Effect of stellate ganglion block on the cerebrovascular system: magnetic resonance angiography study. *Anesthesiology* 113 (4), 936–944. <https://doi.org/10.1097/ALN.0b013e3181ec63f5> (PMID: 20823762).
- Le Bert, N., Clapham, H.E., Tan, A.T., Chia, W.N., Tham, C.Y.L., Lim, J.M., Kunasegaran, K., Tan, L.W.L., Dutertre, C.A., Shankar, N., Lim, J.M.E., Sun, L.J., Zahari, M., Tun, Z.M., Kumar, V., Lim, B.L., Lim, S.H., Chia, A., Tan, Y.J., Tambyah, P.A., Kalimuddin, S., Lye, D., Low, J.G.H., Wang, L.F., Wan, W.Y., Hsu, L.Y., Bertoletti, A., Tam, C.C., 2021 May 3. Highly functional virus-specific cellular immune response in asymptomatic SARS-CoV-2 infection. *J. Exp. Med.* 218 (5), e20202617 <https://doi.org/10.1084/jem.20202617>. PMID: 33646265; PMCID: PMC7927662.
- Li, M., Zhang, Y., Lu, J., Li, L., Gao, H., Ma, C., Dai, E., Wei, L., 2021 Aug 30. Asymptomatic COVID-19 individuals tend to establish relatively balanced innate and adaptive immune responses. *Pathogens* 10 (9), 1105. <https://doi.org/10.3390/pathogens10091105>. PMID: 34578138; PMCID: PMC8468997.
- Lipov, E.G., Navaie, M., Stedje-Larsen, E.T., Burkhardt, K., Smith, J.C., Sharghi, L.H., Hickey, A.H., 2012. A novel application of stellate ganglion block: preliminary observations for the treatment of post-traumatic stress disorder. *Mil. Med.* 177 (2), 125–127.
- Logue, J.K., Franko, N.M., McCulloch, D.J., McDonald, D., Magedson, A., Wolf, C.R., Chu, H.Y., 2021 Feb 1. Sequelae in adults at 6 months after COVID-19 infection. *JAMA Netw. Open* 4 (2), e210830. <https://doi.org/10.1001/jamanetworkopen.2021.0830>. Erratum in: *JAMA Netw. Open.* 2021 Mar 1;4(3): e214572. PMID: 33606031; PMCID: PMC7896197.
- Matschke, J., Lütgehetmann, M., Hagel, C., Sperhake, J.P., Schröder, A.S., Edler, C., Mushumba, H., Fitzek, A., Allweiss, L., Dandri, M., Dottermusch, M., Heinemann, A., Pfefferle, S., Schwabenland, M., Sumner Magruder, D., Bonn, S., Prinz, M., Gerloff, C., Püschel, K., Krasemann, S., Aepfelbacher, M., Glatzel, M., 2020 Nov. Neuropathology of patients with COVID-19 in Germany: a post-mortem case series. *Lancet Neurol.* 19 (11), 919–929. [https://doi.org/10.1016/S1474-4422\(20\)30308-2](https://doi.org/10.1016/S1474-4422(20)30308-2). Epub 2020 Oct 5. PMID: 33031735; PMCID: PMC7535629.
- McQuaid, C., Brady, M., Deane, R., 2021 Jul 14. SARS-CoV-2: is there neuroinvasion? *Fluids Barriers CNS* 18 (1), 32. <https://doi.org/10.1186/s12987-021-00267-y>. PMID: 34261487; PMCID: PMC8278192.
- Medow, M.S., Sood, S., Messer, Z., Dzogbeta, S., Terilli, C., Stewart, J.M., 2014 Nov 15. Phenylephrine alteration of cerebral blood flow during orthostasis: effect on n-back performance in chronic fatigue syndrome. *J. Appl. Physiol.* 117 (10), 1157–1164. <https://doi.org/10.1152/jappphysiol.00527.2014> (1985). Epub 2014 Oct 2. PMID: 25277740; PMCID: PMC4233252.
- Moon, H.S., Lee, H.J., Sung, C.H., Lim, S.J., Choi, J.H., 2007. The efficacy of stellate ganglion block in sensorineural anosmia patients unresponsive to steroid therapy. *Korean J. Pain* 20 (2), 154–157.
- Moon, H.S., Chon, J.Y., Lee, S.H., Ju, Y.M., Sung, C.H., 2013. Long-term results of stellate ganglion block in patients with olfactory dysfunction. *Korean J. Pain* 26 (1), 57–61.
- Mulvaney, S.W., Lynch, J.H., Hickey, M.J., Rahman-Rawlings, T., Schroeder, M., Kane, S., Lipov, E., 2014. Stellate ganglion block used to treat symptoms associated with combat-related post-traumatic stress disorder: a case series of 166 patients. *Mil. Med.* 179 (10), 1133–1140.
- Othman, A.H., Zaky, A.H., 2014 Mar. Management of hot flushes in breast cancer survivors: comparison between stellate ganglion block and pregabalin. *Pain Med.* 15 (3), 410–417. <https://doi.org/10.1111/pme.12331>. Epub 2014 Jan 14. PMID: 24423018.
- Park, H., Kim, D.Y., Bae, J., Lee, S., 2013. The effect of stellate ganglion block on the treatment of sensorineural olfactory disorder following upper respiratory tract infection. *Korean J. Otorhinolaryngol.* 56, 84–89.
- Patterson, B.K., Guevara-Coto, J., Yogendra, R., Francisco, E.B., Long, E., Pise, A., Rodrigues, H., Parikh, P., Mora, J., Mora-Rodríguez, R.A., 2021 Jun 28. Immune-based prediction of COVID-19 severity and chronicity decoded using machine learning. *Front. Immunol.* (12), 700782 <https://doi.org/10.3389/fimmu.2021.700782>. PMID: 34262570; PMCID: PMC8273732.
- Porzionato, A., Emmi, A., Barbon, S., Boscolo-Berto, R., Stecco, C., Stocco, E., Macchi, V., De Caro, R., 2020. Sympathetic activation: a potential link between comorbidities and COVID-19. *FEBS J.* 287 (17), 3681–3688. <https://doi.org/10.1111/febs.15481>. Epub 2020 Aug 1. PMID: 32779891; PMCID: PMC7405290.
- Rahimzadeh, P., Imani, F., Nafissi, N., Ebrahimi, B., Faiz, S.H.R., 2018 Oct 26. Comparison of the effects of stellate ganglion block and paroxetine on hot flashes and sleep disturbance in breast cancer survivors. *Cancer Manag. Res.* 10, 4831–4837. <https://doi.org/10.2147/CMAR.S173511>. PMID: 30464591; PMCID: PMC6208490.
- Rickles, J.A., 1977. Ambulatory use of sympathetic nerve blocks: present day clinical indications. *Angiology* 28 (6), 394–402.
- Song, E., Zhang, C., Israelow, B., Lu-Culligan, A., Prado, A.V., Skriabine, S., Lu, P., Weizman, O.E., Liu, F., Dai, Y., Szigeti-Buck, K., Yasumoto, Y., Wang, G., Castaldi, C., Heltke, J., Ng, E., Wheeler, J., Alfajaro, M.M., Levavasseur, E., Fontes, B., Ravindra, N.G., Van Dijk, D., Mane, S., Gunel, M., Ring, A., Kazmi, S.A.J., Zhang, K., Wilen, C.B., Horvath, T.L., Plu, I., Haik, S., Thomas, J.L., Louvi, A., Farhadian, S.F., Huttner, A., Seilhean, D., Renier, N., Bilguvar, K., Iwasaki, A., 2021 Mar 1. Neuroinvasion of SARS-CoV-2 in human and mouse brain. *J. Exp. Med.* 218 (3), e20202135 <https://doi.org/10.1084/jem.20202135>. PMID: 33433624; PMCID: PMC7808299.
- Sonnweber, T., Boehm, A., Sahanic, S., Pizzini, A., Aichner, M., Sonnweber, B., Kurz, K., Koppelstätter, S., Haschka, D., Petzer, V., Hilbe, R., Theurl, M., Lehner, D., Nairz, M.,

- Puchner, B., Luger, A., Schwabl, C., Bellmann-Weiler, R., Wöll, E., Widmann, G., Tancevski, I., Judith-Löffler-Ragg, Weiss G., 2020 Oct 21. Persisting alterations of iron homeostasis in COVID-19 are associated with non-resolving lung pathologies and poor patients' performance: a prospective observational cohort study. *Respir. Res.* 21 (1), 276. <https://doi.org/10.1186/s12931-020-01546-2>. PMID: 33087116; PMCID: PMC7575703.
- Soriano, J.B., Allan, M., Alsokhn, C., Alwan, N.A., Askie, L., Davis, H.E., Diaz, J.V., Dua, T., de Groote, W., Jakob, R., Lado, M., Marshall, J., Murthy, S., Preller, J., Relan, P., Schiess, N., Seahwag, A., 6 October 2021. A Clinical Case Definition of Post COVID-19 Condition by a Delphi Consensus. World Health Organization.
- Staud, R., Boissoneault, J., Craggs, J.G., Lai, S., Robinson, M.E., 2018. Task related cerebral blood flow changes of patients with chronic fatigue syndrome: an arterial spin labeling study. *Fatigue* 6 (2), 63–79. <https://doi.org/10.1080/21641846.2018.1453919>. Epub 2018 Mar 20. PMID: 29707427; PMCID: PMC5914525.
- Stute, N.L., Stickford, J.L., Province, V.M., Augenreich, M.A., Ratchford, S.M., Stickford, A.S.L., 2021 Sep. COVID-19 is getting on our nerves: sympathetic neural activity and haemodynamics in young adults recovering from SARS-CoV-2. *J. Physiol.* 599 (18), 4269–4285. <https://doi.org/10.1113/JP281888>. Epub 2021 Aug 23. PMID: 34174086; PMCID: PMC8447023.
- ter Laan, M., van Dijk, J.M., Elting, J.W., Staal, M.J., Absalom, A.R., 2013 Sep. Sympathetic regulation of cerebral blood flow in humans: a review. *Br. J. Anaesth.* 111 (3), 361–367. <https://doi.org/10.1093/bja/aet122>. Epub 2013 Apr 24. PMID: 23616589.
- Tian, Y., Wittwer, E.D., Kapa, S., McLeod, C.J., Xiao, P., Noseworthy, P.A., Mulpuru, S.K., Deshmukh, A.J., Lee, H.C., Ackerman, M.J., Asirvatham, S.J., Munger, T.M., Liu, X. P., Friedman, P.A., Cha, Y.M., 2019. Effective use of percutaneous stellate ganglion blockade in patients with electrical storm. *Circ. Arrhythm. Electrophysiol.* 12 (9), e007118 <https://doi.org/10.1161/CIRCEP.118.007118>. Epub 2019 Sep 13. 31514529.
- Tracey, K.J., 2009 Jun. Reflex control of immunity. *Nat. Rev. Immunol.* 9 (6), 418–428. <https://doi.org/10.1038/nri2566>. PMID: 19461672; PMCID: PMC4535331.
- van Campen, C.L.M.C., Verheugt, F.W.A., Rowe, P.C., Visser, F.C., 2020 Feb 8. Cerebral blood flow is reduced in ME/CFS during head-up tilt testing even in the absence of hypotension or tachycardia: a quantitative, controlled study using Doppler echography. *Clin. Neurophysiol. Pract.* (5), 50–58. <https://doi.org/10.1016/j.cnp.2020.01.003>. PMID: 32140630; PMCID: PMC7044650.
- van Campen, C.L.M.C., Rowe, P.C., Visser, F.C., 2020 Jun 13. Cerebral blood flow is reduced in severe myalgic encephalomyelitis/chronic fatigue syndrome patients during mild orthostatic stress testing: an exploratory study at 20 degrees of head-up tilt testing. *Healthcare (Basel)* 8 (2), 169. <https://doi.org/10.3390/healthcare8020169>. PMID: 32545797; PMCID: PMC7349207.
- van Campen, C.L.M.C., Rowe, P.C., Visser, F.C., 2021 Sep 23. Cerebral blood flow remains reduced after tilt testing in myalgic encephalomyelitis/chronic fatigue syndrome patients. *Clin. Neurophysiol. Pract.* (6), 245–255. <https://doi.org/10.1016/j.cnp.2021.09.001>. PMID: 34667909; PMCID: PMC8505270.
- Wells, R., Malik, V., Brooks, A.G., Linz, D., Elliott, A.D., Sanders, P., Page, A., Baumert, M., Lau, D.H., 2020 Dec 15. Cerebral blood flow and cognitive performance in postural tachycardia syndrome: insights from sustained cognitive stress test. *J. Am. Heart Assoc.* 9 (24) <https://doi.org/10.1161/JAHA.120.017861> e017861. Epub 2020 Dec 5. PMID: 33280488; PMCID: PMC7955388.
- White, J.C., 1930. Diagnostic Novocain block of the sensory and sympathetic nerves: a method of estimating the results which can be obtained by their permanent interruption. *Am. J. Surg.* 9 (2), 264–277.